CLINICAL AND EXPERIMENTAL
OPTOMETRY

CLINICAL PICTURE

Optical biometry in a commercially available anterior and posterior segment optical coherence tomography device

Clin Exp Optom 2019 DOI:10.1111/cxo.12880

Piotr Kanclerz MD PhD
Hygeia Clinic, Gdańsk, Poland
E-mail: p.kanclerz@gumed.edu.pl

Submitted: 21 October 2018
Revised: 6 December 2018
Accepted for publication: 13 January 2019

Key words: cataract surgery, measurements, optical coherence tomography, optometry

A difficulty encountered by modern clinics is the necessity to buy a separate optical coherence tomography (OCT) device for anterior/-posterior segment imaging and another for optical biometry. Optical biometry was employed into a commercially available anterior/posterior segment OCT with the new software for Optopol Revo NX OCT (OPTOPOL Technology Sp. z o.o., Zawiercie, Poland).

OCT utilises the principle of low-coherence interferometry; it obtains cross-sectional images by analysing the echo time delay and quantity of the backscattered light of a projected profile. The first widely used clinical applications date back to the 1990s when OCT was used for the imaging of the anterior segment of the eye,[1] the optic disc, and a wide spectrum of macular diseases (including macular oedema, epiretinal membranes, macular holes and age-related macular degeneration).[2] Based on the method employed for light profile analysis, OCT can be divided into time- and spectral-domain (SD). In contrast to the older generation time-domain OCT, SD-OCT implements Fourier analysis to facilitate greater sensitivity and faster image acquisition. Swept-source OCT is a modality of SD-OCT that uses a rapidly tuned laser and a longer wavelength (1,050 nm), thereby allowing increased depth imaging. OCT has the benefits of non-invasiveness, permitting a high degree of repeatability and quick image acquisition. In addition, it does not require mydriasis for examination. Commercially available systems exhibit a speed of over 100,000 scans per second with axial resolution of 1–8 μm. This resolution is far higher than that of conventional clinical technologies such as ultrasound, computed tomography, or magnetic resonance imaging. We observe a wide-scale adoption of OCT, which soon might become a standard of ocular assessment.

Significantly, the first OCT devices were used for measuring the axial length of the eye.[3] However, for several years mainly ultrasonography was applied for pre-operative biometry. The first applicable optical biometry system appeared on the market in autumn 1999.[4] Optical methods for biometry have several advantages. They are less invasive, more user- and patient-friendly, less dependent on the examiner, and demonstrate high levels of accuracy and repeatability.[5] Currently, optical biometry is considered to be the gold standard for pre-operative biometry.

Optopol Revo NX is an SD-OCT device which has an axial resolution of 5 μm, transverse resolution of 12 μm, single scan depth of 2.4 mm, and obtains 110,000 scans per second. A superluminescent laser diode (830 nm) is employed as the light source in this device. The penetration of light through ocular tissues might be similar to that of low-coherence optical reflectometry and better than in partial coherence interferometry biometers. Although currently keratometric measurements and intraocular lens calculation is not available directly within the application, it is to be implemented in future versions of the software. In Figure 1 we present biometry of patients obtained with Optopol Revo NX.

ACKNOWLEDGEMENTS

Dr Kanclerz reports non-financial support from Visim. No conflicting relationship exists between Visim and the author.

REFERENCES

1. Izatt JA, Hee MR, Swanson EA et al. Micrometer-scale resolution imaging of the anterior eye in vivo with optical coherence tomography. *Arch Ophthalmol* 1994; 112: 1584–1589.
2. Hee MR. Optical coherence tomography of the human retina. *Arch Ophthalmol* 1995; 113: 325–332.
3. Fercher AF, Mengedoht K, Werner W. Eye-length measurement by interferometry with partially coherent light. *Opt Lett* 1988; 13: 186–188.
4. Haigis W, Lege B, Miller N et al. Comparison of immersion ultrasound biometry and partial coherence interferometry for intraocular lens calculation according to Haigis. *Graefes Arch Clin Exp Ophthalmol* 2000; 238: 765–773.
5. Chakrabarti A, Nazm N. Update on optical biometry and intraocular lens power calculation. *TNOA J Ophthal Sci Res* 2017; 55: 196.

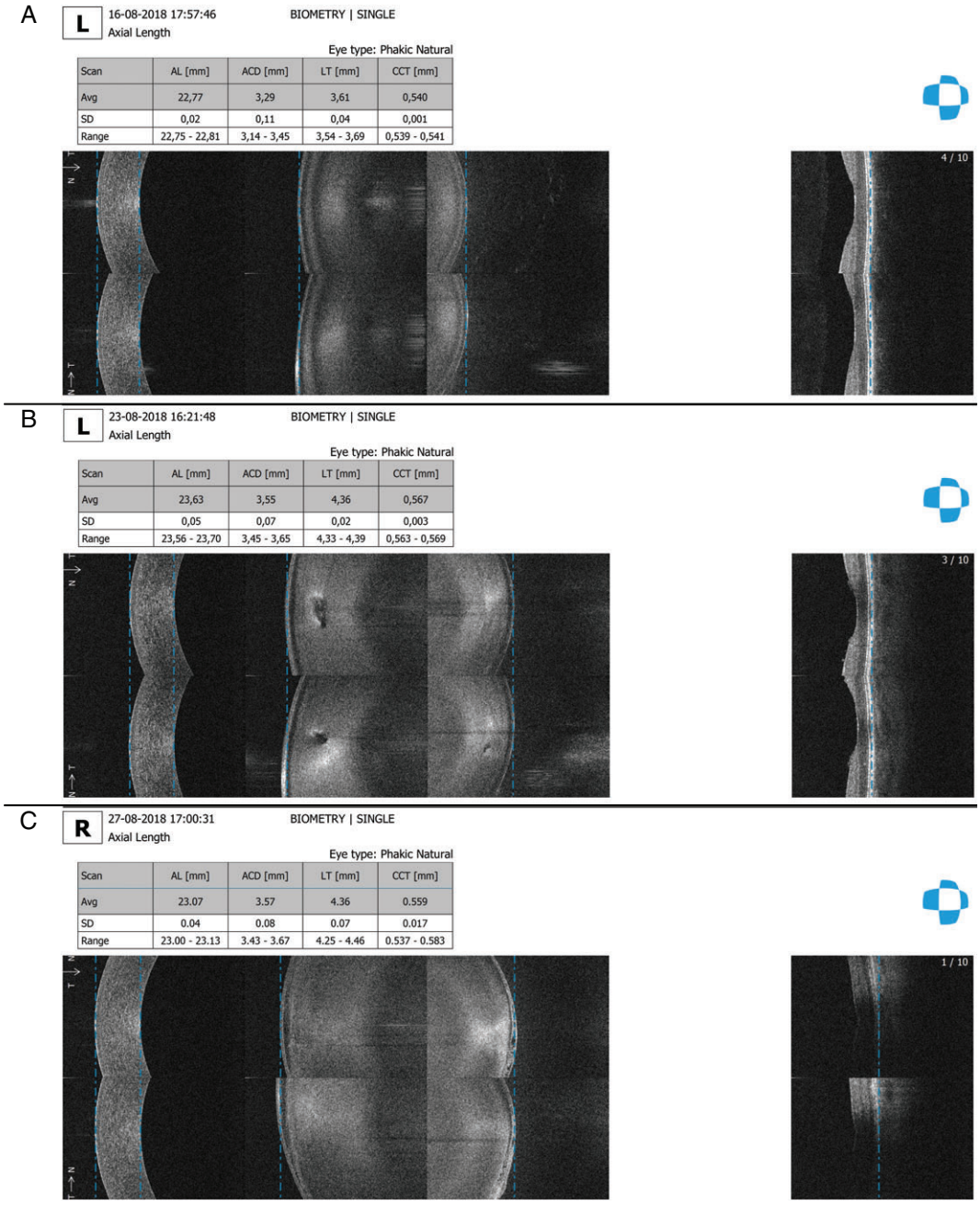

Figure 1. Optical biometry obtained by Revo NX optical coherence tomography. A: The left eye of a 30-year-old healthy woman with a clear lens. B: The left eye of a 69-year-old woman with cortical cataract and a relatively translucent lens nucleus. C: The right eye of a 65-year-old man with dense posterior subcapsular cataract. In cross-sectional images lens opacities can be seen under the posterior capsule. Although the visualisation in the lower and temporal part of the macula is hampered (lower parts of the retinal images), axial length measurements can be obtained.